

# GammaGraft®

human allograft skin

## Introduction

**GammaGraft®** is a sterile, gamma irradiated human allograft skin, that can be stored at ambient temperature. Its main application is that of a temporary biologic skin graft used in burn treatment, and for both acute and chronic wounds of partial and full thickness skin loss, including over exposed bone and tendon.

**GammaGraft®** creates the ideal environment for healing. **GammaGraft®** alleviates the wound site pain and acts as a vapor barrier. It limits fluid, electrolyte, and protein loss from the wound while preventing infection. **GammaGraft®** has both the epidermal and the dermal layers of the skin, an attribute which renders it a more durable and effective barrier against vapor compared to most wound covers, especially to some artificial skins that lack a keratinocyte layer.

The sterilizing process which **GammaGraft®** undergoes produces two key advantages. The irradiation acts to preserve and to sterilize the tissue. This treatment significantly reduces the risk of any viral transmission while also allowing the graft to be stored at ambient temperature for up to three years. Sterilization is an added precaution for the elimination of possible viruses far beyond the extensive serological testing which is conducted by tissue banks for ensuring virus-free skin. Good wound bed preparation is critical for **GammaGraft®** application.

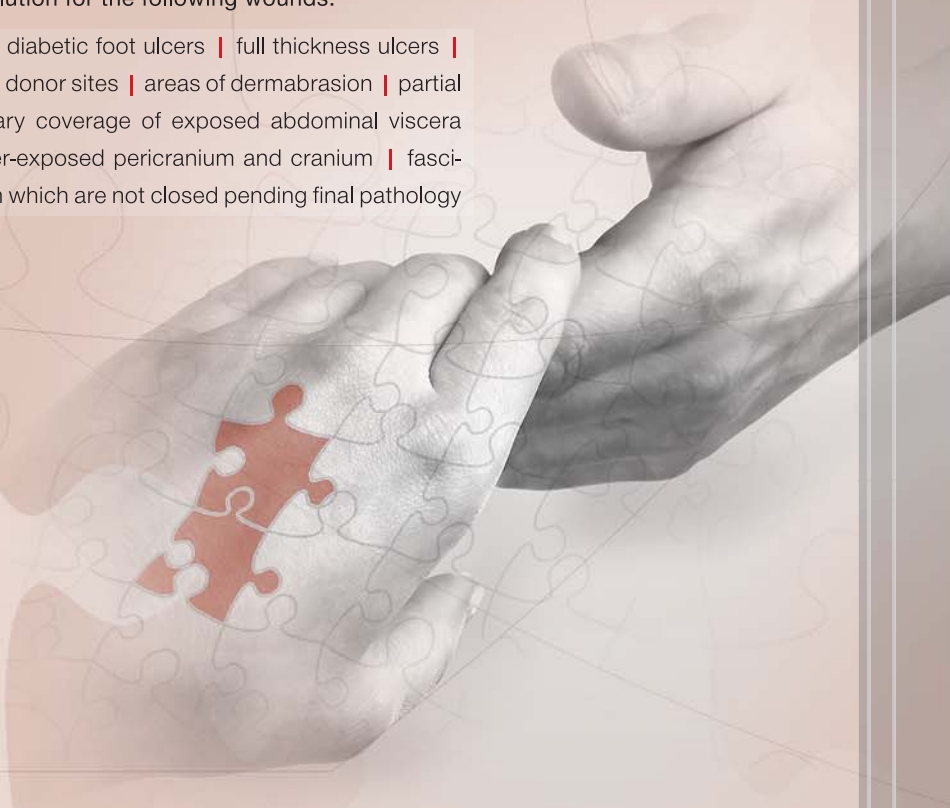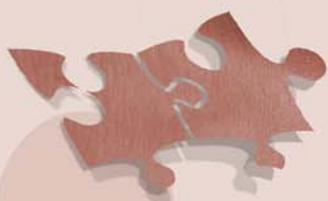Clearing of gross contamination and removal of any necrotic tissue or blister are required before applying **GammaGraft®**. **GammaGraft®** can be applied in clinical settings without the need of costly Operating Room time.

Its transportability, the ease of storage and use, as well as the effective coverage provided by **GammaGraft®** make it a safe and efficacious means of treatment for many types of wounds.

## Common Uses for GammaGraft®

**GammaGraft®** is the ideal solution for the following wounds:

burns | venus stasis ulcers | diabetic foot ulcers | full thickness ulcers | Mohs surgery sites | skin graft donor sites | areas of dermabrasion | partial thickness wounds | temporary coverage of exposed abdominal viscera including small bowel and liver-exposed pericranium and cranium | fasciotomy sites | areas of excision which are not closed pending final pathology report.



# GammaGraft®

human allograft skin

GammaGraft® is available in 4 sizes:

catalog #	usual size coverage
GG 100	1.5 x 1.5 cm
GG 225	2.5 x 3.0 cm
GG 400	4 x 4.5 cm
GG 625	7 x 8 cm, 5 x 12 cm



**McCall**  
**International Medical**

6338 N. New Braunsfels  
San Antonio TX | 78209 | USA

Mobile:

+1.210.710.6795

E-mail:

mattmccall@mac.com

*Respecting  
life!*

www.mimtb.com

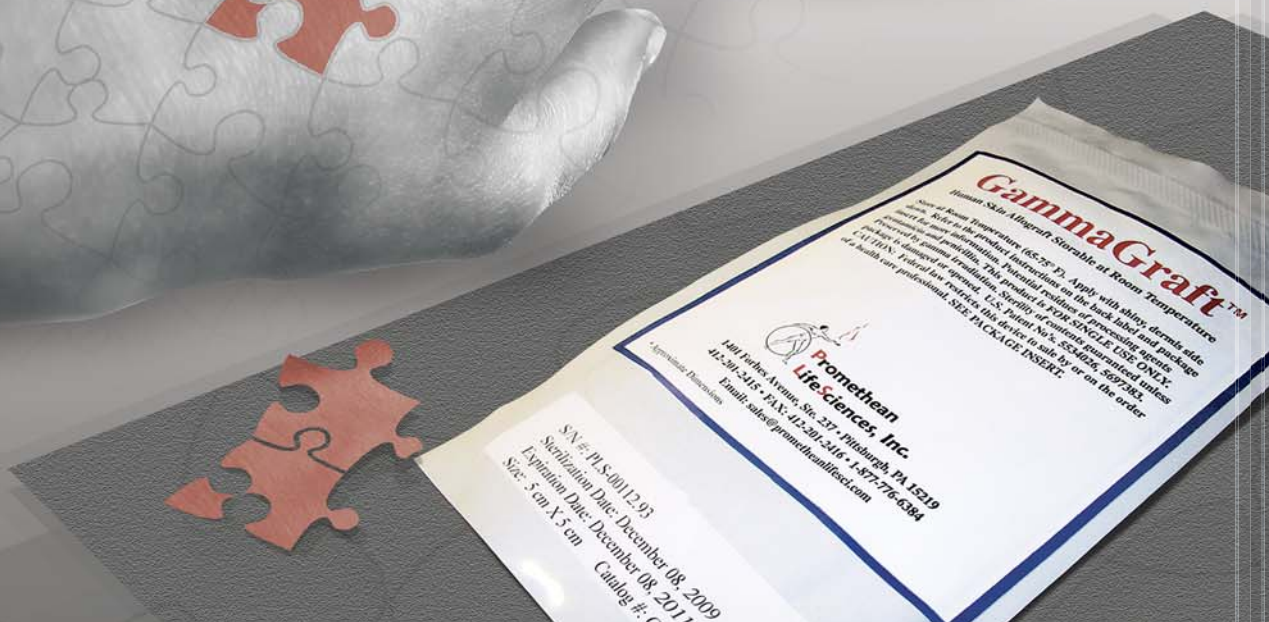
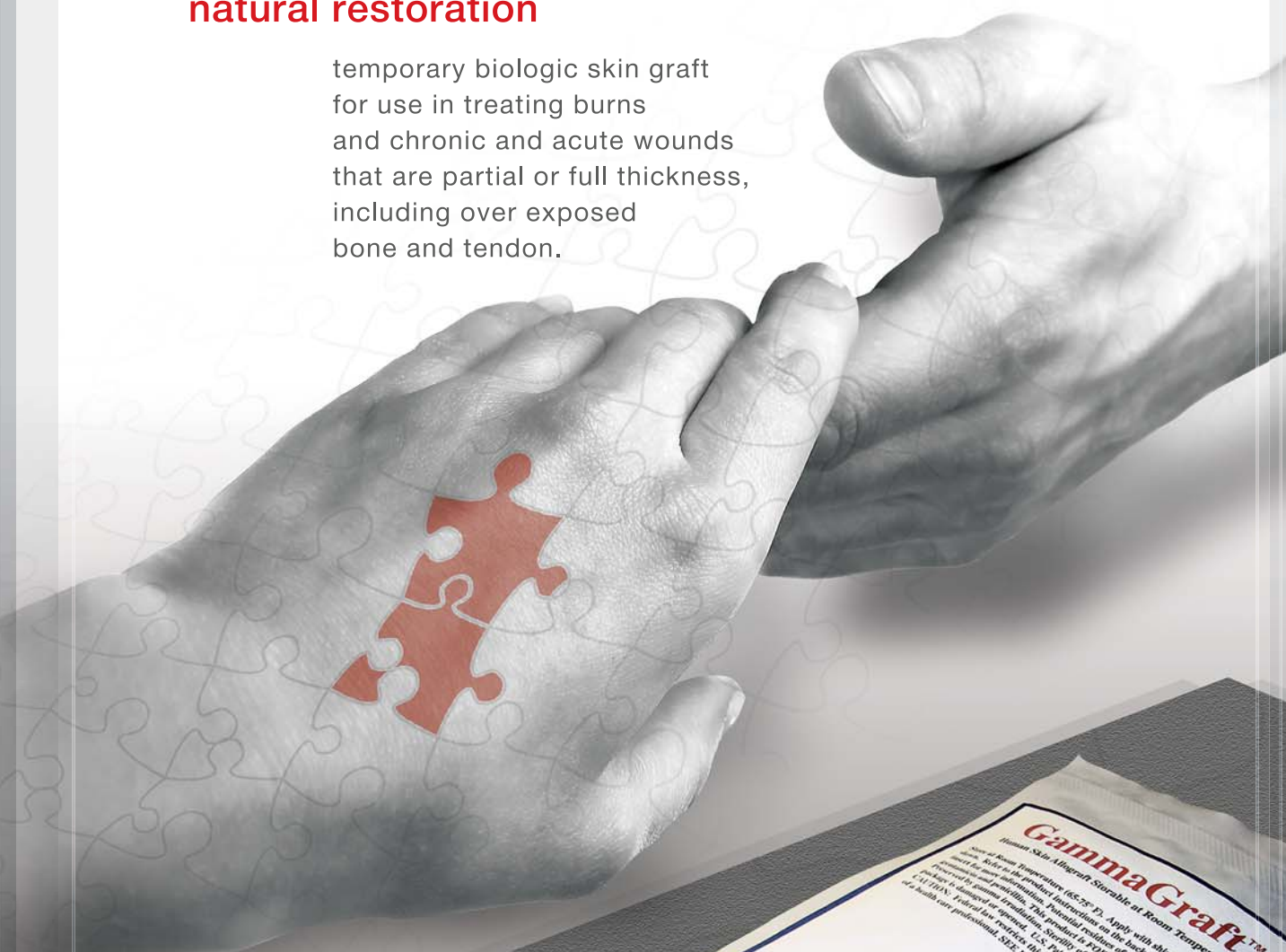
# GammaGraft®

human allograft skin

## complete and natural restoration

temporary biologic skin graft for use in treating burns and chronic and acute wounds that are partial or full thickness, including over exposed bone and tendon.



**GammaGraft™**  
Human Skin Allograft - Storable at Room Temperature

Use at Room Temperature (65-75° F). Apply with skin, dermis side down. Adhere to the Product Instructions on the back label and package insert for many information. Preclinical studies of processing systems showed no immunogenicity. The product is FOR SINGLE USE ONLY. CAUTION: Irritation on opening. U.S. Patent Nos. 5,840,828; 5,929,983 and health care professional. SEE PACKAGE INSERT.



Promethean  
LifeSciences, Inc.  
1401 Forbes Avenue, Ste. 217, Pittsburgh, PA 15219  
412-391-5415 • FAX: 412-391-2416 • 1-877-776-6384  
Email: sales@prometheanlifesciences.com

Approximate Dimensions  
SN #: PL-S2011293  
Sterilization Date: December 08, 2009  
Expiration Date: December 08, 2011  
Size: 5 cm X 5 cm Catalog #: C

# GammaGraft®

human allograft skin

The greatest advantages of **GammaGraft®** are:

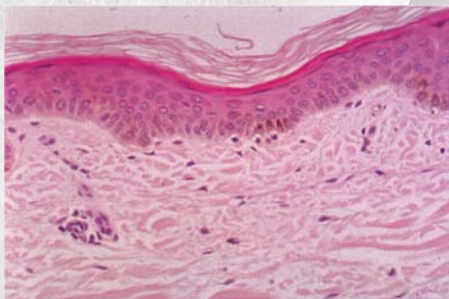
- Creates the ideal wound healing environment
- Two layers: epidermis-dermis
- Keratin layer on the skin acts as a vapor barrier
- Very durable graft with tensile strength like normal skin
- Sterilized with gamma irradiation process
- Stored in ambient temperature
- Ready for use when the package is opened

The presence of keratin layer on the skin acts as a vapor barrier that limits fluid, electrolyte and protein loss from the wound.

**GammaGraft®** naturally adheres due to its retaining its thrombin.

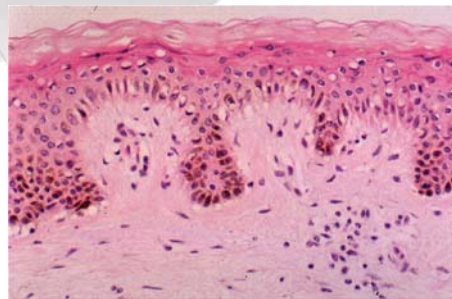
## Histology

**GammaGraft®** is histologically the same as natural skin when observed in the microscopic testing.



skin biopsy.

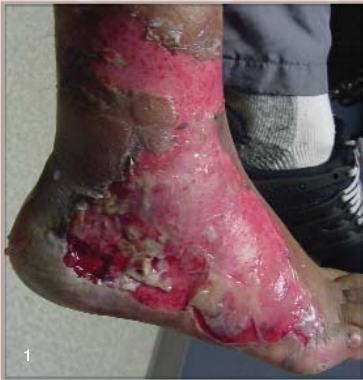**GammaGraft®**



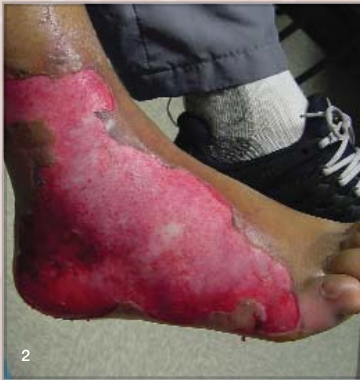after the treatment.

# case study 1

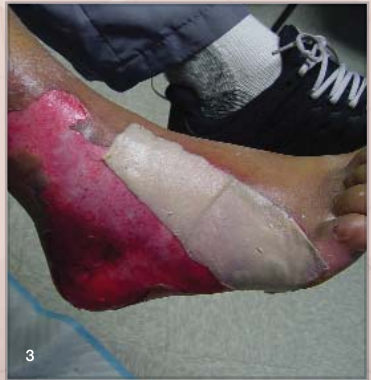## Foot and Ankle burn



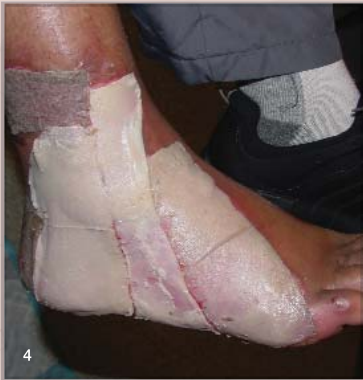1 Before applying **GammaGraft**<sup>®</sup>, the necrotic tissue has to be removed.



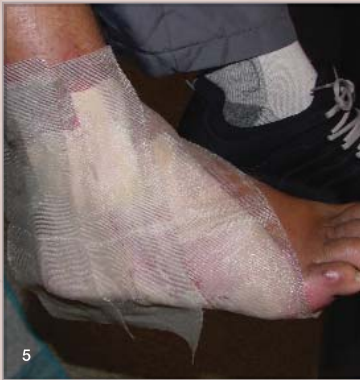2 The wound after the necrotic tissue removal.



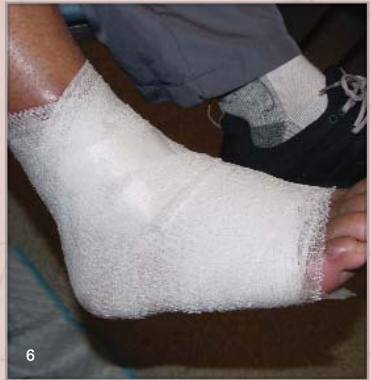3 **GammaGraft**<sup>®</sup> being applied by the doctor.



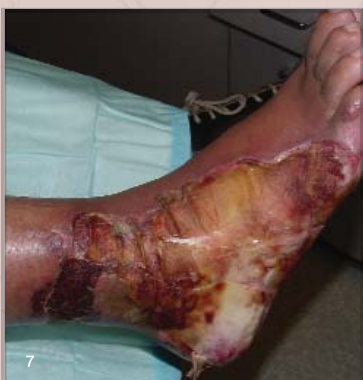4 **GammaGraft**<sup>®</sup> applied to cover the wound margins.



5 Covering **GammaGraft**<sup>®</sup> with non-adherent dressing.



6 Covering with dry gauze. The patient can return home.



7 One week later after allowing the graft to air dry.

**GammaGraft**<sup>®</sup> was applied on the burn above after cleaning the wound and removing the necrotic tissue.

In some parts the patient's healthy skin was covered but after the wound air-dried **GammaGraft**<sup>®</sup> was automatically detached.

Surgical stitches or staples may be used for securing the **GammaGraft**<sup>®</sup>.

Next, **GammaGraft**<sup>®</sup> was covered with a non-adherent dressing and then with rolled gauze.

The patient returned home.

The following day, and after the wound had been air-dried **GammaGraft**<sup>®</sup> created a secure wound cover.

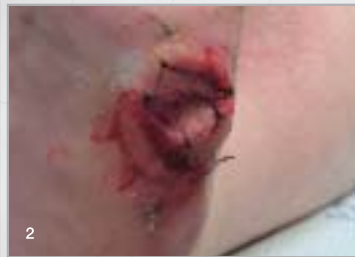

## case study 2

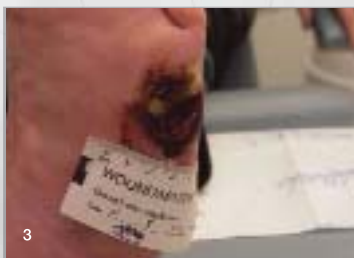### Diabetic foot ulcer patient



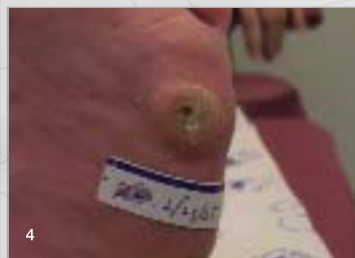1  
Foot ulcer because of diabetes.



2  
GammaGraft® sutured in place.



3  
GammaGraft® after air-dried,  
3 days later.



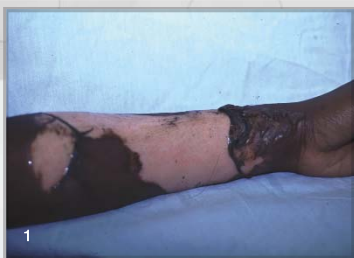4  
Healed ulcer.

This is the foot of a diabetic patient with a chronic wound which could not be healed.

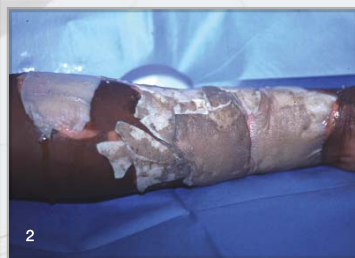The necrotic tissue was carefully cleaned and GammaGraft® was applied, stabilized with stitches and left open to air-dry.

## case study 3

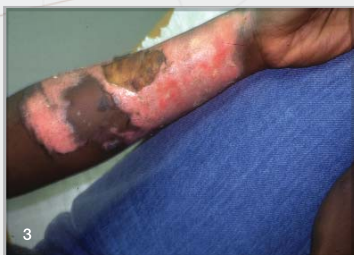### Scald burn



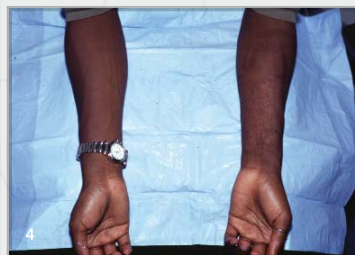1  
Presentation of burn in intensive care.



2  
GammaGraft® application.



3  
GammaGraft® after 14 days.



4  
Long-term results.

This burn was caused by boiling water. During intensive care the necrotic tissue was removed and the wound was covered with GammaGraft®.

The patient returned home. Dressing changes were not needed and the patient kept on with her university cheerleading activities with GammaGraft® already applied.

The third picture was taken 14 days after application.

The greatest part of GammaGraft® had already sloughed off, though a part of it remained in the areas where the burn was deeper.

The repigmentation was stunning while no hypertrophic scarring was observed.